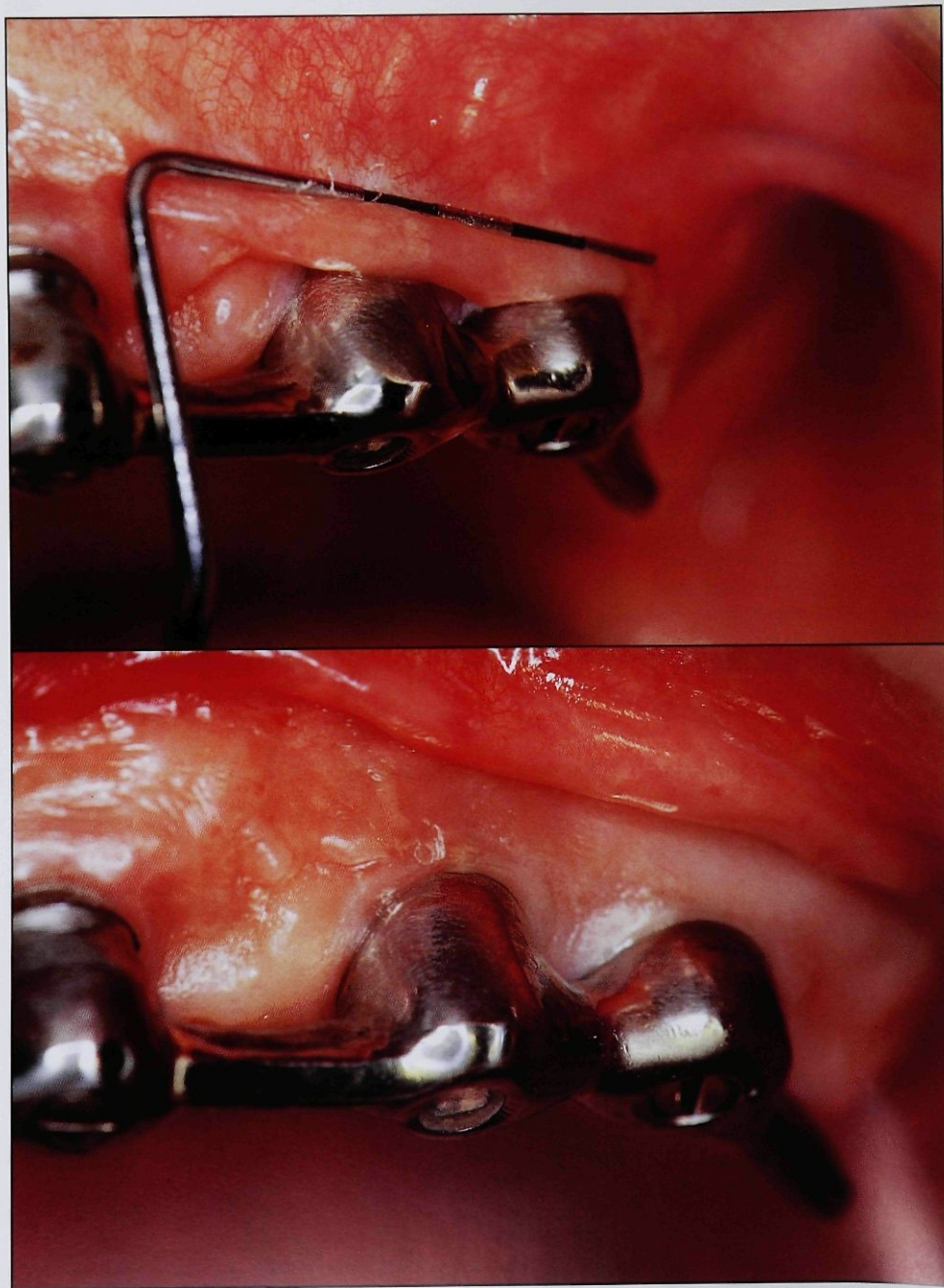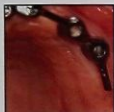


Strip Gingival Autograft Used to Correct Mucogingival Problems Around Implants



Thomas J. Han, DDS, MS*
Perry R. Klokkevold, DDS*
Henry H. Takei, DDS, MS*

This case report describes the use of a strip gingival autograft to transplant narrow strips of keratinized gingiva around dental implants. Replacement of unattached, nonkeratinized mucosa with keratinized gingiva resulted in firmly attached gingiva and an improved seal around implants that was healthier and more resistant to inflammation. The strip gingival autograft technique is a simple surgery that results in less discomfort for the patient and provides predictable results. (Int J Periodont Rest Dent 1995;15:405-411.)

*University of California Los Angeles, School of Dentistry, Los Angeles, California.

Reprint requests: Dr Thomas J. Han, 3540 Wilshire Boulevard, #210, Los Angeles, California 90010.

Numerous studies have documented the success of endosseous dental implants. Few would argue that successful placement of endosseous implants is directly related to tissue acceptance and healing. Many clinicians believe that success of implants depends on integration of implant materials with biologic tissues. In fact, some would like to believe that bone intimately "attaches" to implant materials. Whether bone perceptibly integrates with or intimately tolerates implant materials is yet to be fully elucidated.

The condition of the soft tissues around the crestal portion of the implant and abutment may be just as important to the success and longevity of the implant as the relationship of the underlying alveolar bone to the implant. Plaque has been shown to accumulate around dental implants in a fashion similar to natural teeth. Over time, it goes through a similar pattern of changes from

Gram-positive aerobic colonies to Gram-negative anaerobic colonies, resulting in a peri-implant inflammatory response. Chronic inflammation of peri-implant tissues may lead to breakdown of soft tissue and ultimately to loss of alveolar bone. Again, similar to natural teeth, the soft tissues around the crestal portion of the implant and abutment are thought to be responsible for maintaining a barrier and protecting the bone from bacterial aggression. However, around implants, connective tissue fibers run parallel to the implant surface; around natural teeth, they run perpendicular to and are inserted into cementum and dentin with Sharpey's fibers. Because peri-implant soft tissues have not been shown to attach to the implant or to the abutment, it seems likely that their potential for breakdown is greater than is found around natural teeth. Therefore, the barrier to the progression of inflammation around implants is most likely provided by close adaptation of firm, healthy gingival tissues.¹

The use of free gingival autografts to widen the attached gingiva around natural teeth is considered a very predictable surgical procedure, and the technique has been used extensively since it was first described by Bjorn² in 1963. It has also been used successfully to manage soft tissue defects around implants.³

The conventional free gingival grafting technique consists of obtaining keratinized tissue, usually from the palate, and transferring it to the prepared gingival recipient site.⁴ The size of the donor tissue generally depends on the length and width of the site to be grafted. When the area to be covered extends beyond the width of a single tooth or implant, the donor site becomes large. The ensuing open wound is difficult to protect and often results in postoperative pain and bleeding. Various techniques for the protection and coverage of the donor site have been utilized; each has advantages and disadvantages.⁵ Regardless of the protective procedure used, the process of healing by secondary intention of a large donor site is painfully slow. The following case report describes the use of strip gingival autografting to provide a large area of attached keratinized tissue around implants with minimal discomfort to the patient.⁶

Case report

A 50-year-old healthy Asian woman, who had six endosseous dental implants that had been placed in the anterior maxilla about 4 years previously, presented with chronic pain and inflammation of peri-implant soft tissues. She had lost one implant within the first year to peri-implant bone loss or poor integration. The remaining five implants were stable and adequately restored with a cast metal bar and an overdenture with clips.

Examination revealed peri-implant tissues consisting of generalized loose, nonkeratinized mucosa on the labial aspect (Fig 1) and healthy keratinized tissue on the palate. There were several focal areas of inflammation around the labial surface of the implants. The patient was generally pleased with her implants and the implant-supported denture, except when the peri-implant tissues became inflamed and painful. The loose, nonkeratinized tissues were often pinched and folded under the denture, causing discomfort and inflammation (Fig 2). The patient complained that the problem recurred about every 2 to 3 months, each time requiring relief of the denture and addition of a soft liner for a period of time until the tissue inflammation resolved. When

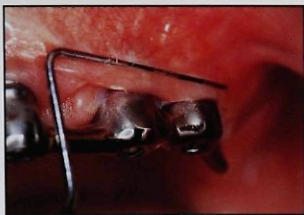
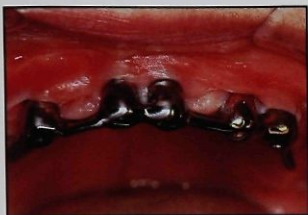


Fig 1 (left) Presurgically, the implant patient has a mucogingival problem. Keratinized gingiva is lacking around the facial aspect of implants.

Fig 2 (right) The implant has very mobile nonkeratinized tissue that is pinched under the denture when the tissue is inflamed.

tissue comfort returned, the denture was again relined with acrylic resin.

After many months and several such palliative treatments, the patient was referred for evaluation and treatment of inflamed and painful peri-implant soft tissues. Probing depths ranged from 2 to 5 mm. The implants were firm, and the fit of the prosthesis was adequate. Once the initial inflammation had subsided, the surgical correction of the problem was considered. Because of the extent of graft tissue needed to treat these five implants, it was decided to use the strip autograft technique to replace the loose peri-implant mucosal tissue with firm keratinized gingiva.

Surgical technique

Recipient site preparation. The initial incision for the preparation of the recipient site must be made in keratinized gingiva coronal to the mucogingival junction. Owing to the lack of attached gingiva around the implants, the initial incision was made at the crest of gingiva on the radicular surfaces (Fig 3). The length of the incision, determined by the number of implants involved, should extend approximately 5 to 10 mm distal to the implant (Fig 4). The incision was terminated with a slight apical curvature to provide easier release of the mucosal tissue. A partial-thickness flap was then reflected in such a way that a firm, stable periosteum was left on the recipient site. If loose connective tissue is left on the recipient site, the resultant keratinized tissue will be mobile.

The apical mucosal border of the recipient site was sutured down to the periosteum with a thin gut suture. A vertical mattress suture was placed in the mucosal edge of the incision and then a horizontal mattress suture was placed in the periosteal tissue at the apical end of the recipient site before a knot was tied.

Managing the recipient site in this manner provides several advantages. It delineates the recipient site, making it easier to manage flaps during surgery; it minimizes the formation of a pouchlike area during the healing phase; and it provides hemostasis when the mucosal tissue is sutured to the periosteum at the apical borders of the recipient site. Because in this technique the donor tissues are not sutured to the recipient bed, excessive bleeding makes it very difficult to stabilize the donor tissues.

Fig 3 (left) At the recipient site, the mucosal flap is fixed to the apical end of the firm periosteal bed. The incision is at the gingival crest.

Fig 4 (right) The recipient site is extended 5 to 10 mm distal to the last implant.

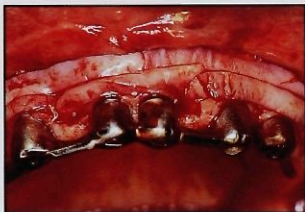
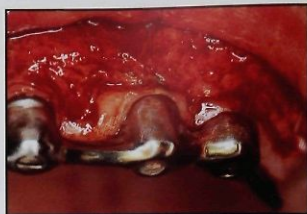
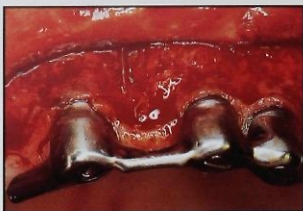Fig 5 Strip grafts are placed over the recipient site.

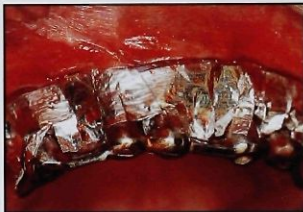

Fig 6 Dry foil is placed over the grafts to keep them in place.

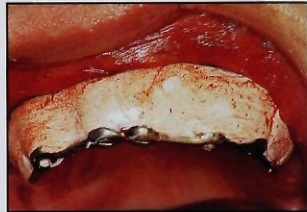

Fig 7 Periodontal dressing is applied over the dry foil while the dressing is still soft.

Donor site. After the recipient site was prepared, the length of the area to be covered was measured and the donor site was approached. Because the area of the recipient site was large, donor tissues were obtained from both sides of the palate. Five parallel strips of palatal donor tissue were removed. Leaving intact palatal tissue between the donor strips facilitates healing. These strips were approximately 2 mm wide and as thin as possible (approximately 0.50 to 0.75 mm thick). The donor sites were left

without sutures or dressing. Because the strips were thin, postoperative bleeding and discomfort from the donor sites were not a problem.

Transfer of strip grafts. The donor strips were then transferred to the recipient site. The epithelial side should be noted, because it is difficult to recognize the difference. The strips were placed with their connective tissue side against the recipient bed, one in a coronal position and the other in a more apical position. With adequate hemostasis and strips of

proper thickness, the strip gingival autografts adapted and adhered well to the recipient site (Fig 5).

A gut mattress suture from the apical portion of the recipient site to the coronal portion may be used to keep the strips stabilized during the healing period, but the best way to provide stability and protection of the donor tissue and the recipient site is the use of dry foil and surgical packing. Dry foil was trimmed to fit into the apical border of the recipient site. The coronal portion of the foil was

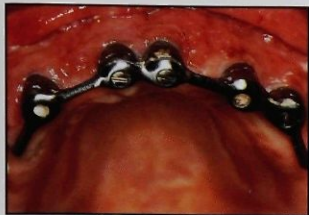

Fig 8 The recipient site is almost completely epithelialized 1 week postoperatively.

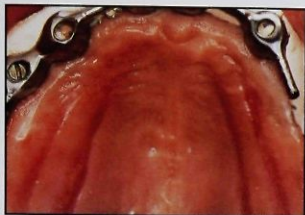

Fig 9 The donor site is healing rapidly 1 week postoperatively.

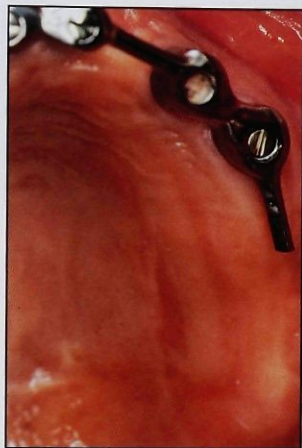


Fig 10 The donor site is completely epithelialized 2 weeks postoperatively.

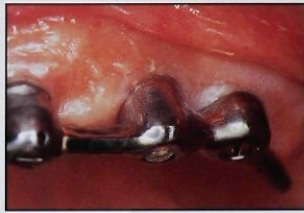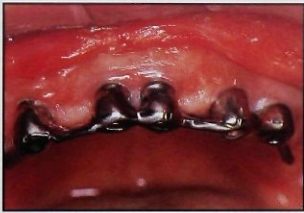serrated to facilitate adaptability of the foil into the embrasures between the implants. The sticky surface of the foil keeps the strips against the recipient site, and it also prevents the dressing from dislodging the graft tissue (Fig 6). The periodontal dressing was placed over the foil while the dressing was still soft so that it could be molded by the lips and vestibule. The dressing was pressed into embrasures to provide retention (Fig 7).

Postoperative healing

Postoperative care. The initial postoperative visit was 7 days after surgery. The patient had been instructed not to brush the area or chew on the site of surgery and the dressing stayed on, but it had become loose. In 1 week the recipient site showed some superficial sloughing, but the wound was almost completely epithelialized (Fig 8). A chlorhexidine oral rinse was prescribed for 1 week. The patient returned to normal brushing in 2 weeks. Minimal

discomfort was associated with the surgery at the recipient site. The donor site was rapidly epithelialized (it usually is within 10 days), and, unlike the donor site of conventional free gingival autografts, it produced minimal discomfort to the patient (Fig 9).

After 2 weeks, the donor site showed complete epithelialization. Except for a change in color, the sites were almost imperceptible (Fig 10). The recipient site showed excellent healing and increased keratinized attached gingiva in 2



Figs 11a and 11b At the grafted site 2 weeks postoperatively, the contours of the strips are evident, but the healing is excellent.

weeks (Fig 11a). The area covered by the newly attached tissue was fairly homogenous, but remnants of the strips' contours were evident (Fig 11b). Presence of firm keratinized tissue provided a tighter seal around the implants and it was easier for the patient to maintain proper oral hygiene. Inflammation, bleeding on probing, and peri-implant probing depths decreased. Subsequently, the patient was comfortable and without complaints.

Discussion

The position and angulation of dental implants has become increasingly important to the esthetic and functional result of the dental prostheses. Placement of implants in prostheti-

cally accurate positions occasionally results in emergence of abutments through nonkeratinized and often unattached mucosa. Although many believe that this is not a problem, studies have yet to determine the effects of mucogingival problems around dental implants. In a retrospective analysis, Block and Kent⁷ found that keratinized gingiva around dental implants positively correlated with optimal soft and hard tissue health. They found that crestal bone loss around implants (in the posterior mandible) was strongly correlated with bleeding on probing, probing depths of greater than 3 mm, and lack of keratinized gingiva adjacent to the implants.

Keratinized attached gingiva can be predictably provided around implants with the

use of free gingival or connective tissue autografts. However, a conventional free gingival autograft of this magnitude often leaves a painful donor site, requiring special procedures to decrease the patient's discomfort, which can last 3 or 4 weeks.

The advantage of the strip technique is that it creates minimal trauma to the donor site, resulting in less bleeding and discomfort. Studies on wound healing⁸ have indicated that epithelial cells migrate from adjacent epithelium to cover the open wound. Therefore, the donor site should heal rapidly when the donor tissues are removed in strips regardless of the length or number of the strips because the epithelium has a shorter distance to travel and more margins from which to migrate.

It has been observed clinically that the total amount of keratinized attached gingiva gained with this technique is roughly equivalent to the total widths of the strips placed on the recipient site. Regardless of the width of the prepared recipient site or the way in which the strips are positioned on the recipient bed, within 3 months condensing of the strips can be observed with the consequent coronal migration of the mucogingival junction to a width similar to the total width of the donor strips. This observation confirms the results of post-operative studies on alteration of vestibular depth.⁹

Summary

With the strip gingival autograft, extended areas with mucogingival problems can be treated in one appointment, which makes it a very practical technique. This technique consistently provides a wider zone of keratinized gingiva and promotes a tight seal of firm tissue around implants for improved health.

References

1. Buser D, Weber HP, Donath K, Fiorellini JP, Paquette DW, Williams RC. Soft tissue reactions to non-submerged unloaded titanium implants in Beagle dogs. *J Periodontol* 1992;63: 225-235.
2. Bjorn H. Free transplantation of gingiva propria. *Sveriges Tandlaek Tidn* 1963;22:684.
3. Rapley JW, Mills MP, Wylam J. Soft tissue management during implant maintenance. *Int J Periodont Rest Dent* 1992;12:373-381.
4. Carranza FA Jr. Glickman's Clinical Periodontology, ed 7. Philadelphia: Saunders, 1990.
5. Farnoush A. Technique for the protection and coverage of the donor sites in free soft tissue grafts. *J Periodontol* 1978;49:403-405.
6. Han TJ, Takei HH, Carranza, FA. The strip gingival autograft technique. *Int J Periodont Rest Dent* 1993; 13:180-187.
7. Block, MS, Kent, JN. Factors associated with soft- and hard-tissue compromise of endosseous implants. *J Oral Maxillofac Surg* 1990;48: 1153-1160.
8. Oliver R, Loe H, Karring T. Microscopic evaluation of the healing and revascularization of free gingival grafts. *J Periodont Res* 1968;3:84-95.
9. Bohannon HM. Studies in the alteration of vestibular depth. II. Periosteum retention. *J Periodontol* 1962; 33:354-359.